



# Clinico-Hematological and Biochemical Studies on Naturally Infected Camels with Trypanosomiasis

Riaz Hussain,<sup>1</sup> Ahrar Khan,<sup>2\*</sup> Rao Zahid Abbas,<sup>1</sup> Abdul Ghaffar,<sup>3</sup> Ghulam Abbas,<sup>4\*</sup> Tuseef ur Rahman<sup>1</sup> and Farah Ali<sup>1</sup>

<sup>1</sup>University College of Veterinary and Animal Sciences, The Islamia University of Bahawalpur-63100, Pakistan.

<sup>2</sup>Department of Pathology, University of Agriculture, Faisalabad-38040, Pakistan

<sup>3</sup>Department of Life Sciences (Zoology), The Islamia University of Bahawalpur- 63100

<sup>4</sup>Centre of Excellence in Marine Biology, University of Karachi, Karachi-75270, Pakistan

## ABSTRACT

Blood borne protozoan diseases such as trypanosomiasis have negative impacts on health, production and working efficiency of camels in different camel-rearing areas of the world including Pakistan. In the present study, blood samples were collected from camels kept at desert condition of Cholistan to estimate the prevalence of trypanosomiasis and hemato-biochemical changes in naturally infected cases. Results showed an overall 9.67% prevalence of trypanosomiasis in camels. Various clinical signs such as pyrexia, occasional shivering, inappetence, urticarial swelling, lethargy, going down in condition and edema of pads were observed in few cases. The statistical analysis did not show significant association of age and sex with trypanosomiasis. However, the results revealed significantly decreased values of total erythrocyte counts, packed cell volume, hemoglobin concentration, mean corpuscular hemoglobin concentration, serum total proteins and albumin while increased values of mean corpuscular volume was recorded in infected animals as compared to healthy ones. A significant ( $P < 0.01$ ) increased values of total leukocyte count, monocytes, lymphocytes, neutrophils and eosinophils was recorded in the infected animals. Moreover, microscopic examination of blood films obtained from naturally infected cases showed presence of parasite and various morphological changes in cells such as stomatocyte, hypochromia and polychromia. Significantly increased values of different hepatic enzymes including alanine aminotransferase, aspartate aminotransferase and alkaline phosphatase were also recorded.

## Article Information

Received 27 February 2015  
Revised 29 September 2015  
Accepted 13 October 2015  
Available online 1 March 2016

## Authors' Contributions

RZA executed the experiment work.  
AG performed haematological studies. TR and FA analyzed the data. AK and GA wrote the article. RH supervised the work.

## Key words

Camel, trypanosomiasis, hematological indices, serum enzymes.

## INTRODUCTION

*Trypanosoma evansi* which multiplies in blood and other body fluids is the most widely spread of an endemic disease (surra) of camels and different domestic animals throughout the world (Elhaig *et al.*, 2013; Rodriguez *et al.*, 2012; Shahid *et al.*, 2013). Trypanosomes are blood and tissue parasites of order Kinetoplastida and family Trypanosomatidae which are found in different mammals including humans (Coura and Borges-Pereira, 2010; Dyary *et al.*, 2014). *Trypanosoma*, are mainly transmitted to animals by biting insects (*Tabanus*, *Stomoxys* and *Liperosia*) in which they undergo a biological cycle. *Trypanosoma* flagellate protozoan parasites induce anemia, fever, depression, dullness, weakness, nervous symptoms and are responsible for major economic losses in terms of poor production (milk, meat, fertility, draught power and manure) and sometimes abortion or death in case of no

treatment. Currently animal Trypanosomoses are a stable constraint for different livestock animals throughout the world including Latin America, Africa and Asia however, their biological distribution is still evolving (Desquesnes *et al.*, 2013). Camel trypanosomiasis is present in India, Mongolia, China, Thailand, Russia, Nepal, Vietnam, Bhutan, Cambodia, Myanmar, Malaysia, Indonesia, the Philippines, South America and Europe (Reid, 2002; Salim *et al.*, 2011; Desquesnes *et al.*, 2013). Trypanosomiasis in camels may be acute with high fever, weakness, anemia, high morbidity and high mortality (Enwezor and Sackey, 2005). The acute form of disease is generally fatal, while the chronic form is more common and associated with secondary infection. Haemoparasitic diseases like trypanosomiasis have adverse influence on health and working capability of camels in large areas of Africa (Mihret and Mano, 2007), economically importance in Indian subcontinent (Sood *et al.*, 2011) and South Asian countries (Konnai *et al.*, 2009; Ismael *et al.*, 2014). Anemia induces anoxic situations in infected animals and ultimately leads to progression of weakness which manifests signs of dysfunction in numerous organs including liver and release of different enzymes especially alanine aminotransferase and

\* Corresponding authors: [abbas.cemb@yahoo.com](mailto:abbas.cemb@yahoo.com) - [ahrar1122@uaf.edu.pk](mailto:ahrar1122@uaf.edu.pk)

0030-9923/2016/0002-0311 \$ 8.00/0

Copyright 2016 Zoological Society of Pakistan

aspartate aminotransferase (Olaho-Mukani and Mahamat, 2000; Soyly, 2013). Pakistan is ranked at third position among camel rearing countries and have about 1.2 million heads of camels. The majority of camels in Pakistan are present in Balochistan (41%) which are particularly raised for draught purposes (Ali *et al.*, 2009). In Pakistan, in addition to military campaigns dromedaries are good source of income, means of poverty alleviation particularly for the people living in deserts areas through milk, meat, wool, hides and carriage of crops. Out of 17.40 million world camel population about one million heads of camels are present in different areas of Pakistan (Anonymous, 2013-14). Because of the widespread geographic range of distribution, its control has got international attention, with a focus on formulating and implementing effective approaches aimed at enhancing productivity and accomplishing a decline in mortality and morbidity (Enwezor and Sackey, 2005). Keeping in view the importance of trypanosomiasis in camels, this study was conducted to know the prevalence, clinico-hematological and biochemical changes in naturally infected camels with trypanosomiasis.

## MATERIALS AND METHODS

### *Examination of the camels*

A total of 217 camels kept in two different herds including Pakistan Rangers Force at desert conditions of district Bahawalpur, Pakistan were examined and screened for presence of *Trypanosoma* flagellate protozoan parasites between July and September 2014. The camels are usually kept under similar natural desert conditions of Cholistan. All the camels were thoroughly examined for any clinical ailment prior to sampling. Various physical parameters such as body condition, temperature, pulse rate, respiration rate and hump status were recorded. Different clinical signs in trypanosomiasis positive case were also observed.

### *Blood collection and parasitological examination*

Blood samples were collected from the jugular vein of each camel following the guide line of International Animal Ethic and Welfare Committee To detect the flagellated protozoan trypanosomes. Fresh thin smears were made using glass slides immediately after collection of blood (Khan *et al.*, 2013; Asi *et al.*, 2014). All the smears were air dried, fixed with absolute methanol and finally stained with Giemsa stain (El-Dakhly *et al.*, 2013). Various morphological changes such as droplet cells, elliptical cells, macrocyte and microcyte in erythrocyte of infected camel were also observed with the help of light microscope.

### *Hematological and biochemical studies*

For hematological and biochemical studies blood samples were collected with and without anticoagulant (EDTA; 1mg/ml). Serum was separated from the blood samples which were collected without anticoagulant. The blood samples those were collected with anticoagulant were used to determine different hematological parameters (Qureshi *et al.*, 2013; Ali *et al.*, 2014; Gad and El-Maddawy, 2014). Total erythrocyte counts (TEC), total leukocyte counts (TLC), packed cell volume (PCV), hemoglobin concentration (Hb), mean corpuscular hemoglobin concentration (MCHC) and differential leukocyte count (DLC), such as monocyte, lymphocyte, neutrophils and eosinophils were estimated as previously described (Ghaffar *et al.*, 2014). Different serum biochemical parameters such as serum total proteins, albumin and various enzymes like alanine aminotransferase (ALT), aspartate aminotransferase (AST) and alkaline phosphatase (ALP) were determined (Hussain *et al.*, 2014). The information about each camel including age and sex was also recorded.

### *Statistical analysis*

The data regarding prevalence was analyzed by frequency analysis using chi-square test, where appropriate odd ratio and 95% C.I. was also computed. Data on hematological and serum biochemical parameters were analyzed by Student's t-test, using SPSS,  $P < 0.05$  was considered significant.

## RESULTS AND DISCUSSION

Various clinical signs such as fever, occasional shivering, inappetence, urticarial swelling, lethargy, going down in condition and edema of pads were observed in some infected cases. Previously different clinical signs including anemia, poor body conditions, urticaria, edema and petechial hemorrhages of serous membranes have been observed in naturally and experimentally infected animals (Reid *et al.*, 2001; Mijares *et al.*, 2010; Padmaja, 2012). Results of the present study showed that out of 217 blood samples 21 (9.67%) were presumed to be positive for *Trypanosoma evansi* flagellated protozoan parasite. Sex-wise statistical analysis showed that there was no significant association in prevalence of trypanosomiasis in male and female animals. Out of total animals examined 8 (8.99%) male and 13 (10.15%) female were positive. The statistical analysis also did not show significant association of age with trypanosomiasis. The results of this study showed non significant higher prevalence of trypanosomiasis in camels of age group  $>8$  years on the basis of different age groups (Table I). The overall prevalence of

**Table I.- Bivariate frequency analysis of different parameters in trypanosomiasis positive and healthy camels.**

Parameters	Positive		Negative %	95% CL	MH Chi-sq P value	OR/ reciprocal
	n	%				
<b>Sex</b>						
Male	8	8.99	81	4.26- 16.35	-	0.87/1.14
Female	13	10.15	115	5.77- 16.33	-	
Total	21	9.67	196	6.25-14.17	-	
<b>Age groups</b>						
1.0-2.0	2	7.40	25	1.26-22.38	P = 0.290	-
2.1-5.0	3	7.69	36	1.99-19.52		
5.1-8.0	5	7.46	62	2.79- 15.76		
8.1 -10.0	7	13.72	44	6.21- 25.27		
10.1-15.0	4	12.12	29	3.97- 26.70		

trypanosomiasis in present study is lower as compared to different investigations made by (Shah *et al.*, 2004; Bhutto *et al.*, 2010; Aslam *et al.*, 2010) and higher as reported by (Murtaz *et al.*, 2006) in camels in different areas of Pakistan. Previously higher prevalence of trypanosomiasis in camels have been reported in different countries of the world such as Southwest Ethiopia (Bogale *et al.*, 2012), in eastern Ethiopia (Zelege and Bekele, 2001), in Niger (Pacholek *et al.*, 2001), in Kenya (Enwezor and Sackey, 2005), Jordan (Al-Rawshdeh *et al.*, 2003), in Sudan (Elamin *et al.*, 1998; Rami *et al.*, 2003), in mid-Eastern Sudan (Salim *et al.*, 2011) and in Kenya (Njiru *et al.*, 2002). The prevalence of parasite trypanosomes in present study was higher as previously reported in India (Pathak *et al.*, 1993), eastern Ethiopia (Tadesse *et al.*, 2012; Zayed *et al.*, 2010). No significant difference in prevalence of trypanosomiasis between sex categories was recorded. These findings are similar to the investigations made by Bogale *et al.* (2012). Previously in Pakistan higher prevalence of *Trypanosomiasis* was recorded in female than among male (Bhutto *et al.*, 2010). However, previous studies in Asia have reported significant sex related prevalence of *Trypanosomiasis* more in females as compared to males (Shah *et al.*, 2004). Results of this study showed that no significant difference in the prevalence of parasitism between different age groups was recorded. However, the infection rate was higher in old camels as compared to young camels. The increased rate of prevalence in old camels could be due to poor management, movement from one place to another and heavy stress through transportation of goods. Similar reports are also available (Shah *et al.*, 2004; Kassa *et al.*, 2011; Bogale *et al.*, 2012). In contrast to our results relatively higher prevalence of infection was recorded in young age groups than adult camels (Kassa *et al.*, 2011).

Mean values of different hematological parameters such as TEC, hemoglobin concentration, PCV, MCV, MCHC, TLC, neutrophils, monocytes, lymphocytes, eosinophils and basophils are illustrated in Table II. Results showed that TEC, hemoglobin concentration and PCV was significantly decreased in trypanosomiasis positive camels when compared to healthy camels. Mean values of MCV were significantly increased while MCHC was decreased in *T. evansi* positive camels. Severe leukocytosis, neutrophilia, monocytosis, eosinophilia and basophilia were recorded in positive camels as compared to non infected camels. A significant ( $P < 0.01$ ) decreased values of monocytes was also recorded in infected animals. The lower hematological values including erythrocyte count, hemoglobin concentration and PCV are suggestive of anemia and have been reported in *Trypanosomiasis* positive camels (Mijares *et al.*, 2010; Abd El-Baky and Salem, 2011; Padmaja, 2012; Eyob and Matios, 2013). Previously anemia (Mijares *et al.*, 2010), lower total serum proteins, lymphocytes number and neutrophilia were observed in *T. evansi* infected camels (Shafqaat *et al.*, 2004; Padmaja, 2012). Anemia is considered as a major and important indicator of trypanosomiasis infection in camel and in human African trypanosomiasis. The anemia occurs due to parasitic infection which causes large number of erythrocyte to be removed due to mononuclear phagocytic response in spleen and haemal lymph nodes (Eyob and Matios, 2013). This removal of erythrocytes also leads to decrease in PCV and vascular dysfunction ultimately resulting to severe anoxic conditions (Eyob and Matios, 2013). Moreover anemia also causes increased oxidation of erythrocytes which are carried out by membrane damage, destruction of cell during chronic infection and osmotic fragility (Gutierrez *et al.*, 2005). Decreased values of MCHC, increased

MCV, lymphocytosis and leukocytosis also have been reported in positive camels (Abd El-Baky and Salem, 2011; Eyob and Matios, 2013).

**Table II.- Analysis of various hematological and some serum biochemical parameters(Mean±SD) of healthy and infected camels.**

Parameters	Healthy	Infected	P-values
Total erythrocyte	7.44±1.04	4.25±0.07	<0.01
Hb concentration	12.61±0.12	8.18±1.04	<0.001
Packed cell volume	40.71±0.55	25.7±1.22	<0.01
MCV	28.21±2.50	38.36±2.49	<0.01
MCHC	50.24±4.67	36.09±3.42	<0.01
Total leukocyte	12.33±1.27	19.25±2.44	<0.01
Neutrophil	30.57±2.44	42.37±3.45	<0.001
Monocyte	2.64±0.02	4.15±0.06	<0.01
Eosinophil	2.28±0.01	4.51±0.12	<0.01
Basophil	0.83±0.02	1.34±0.02	<0.01
Lymphocyte	57.53±2.58	40.51±2.82	<0.01
Total proteins	7.35±0.09	5.09±0.06	<0.01
Albumin	3.85±0.03	2.64±0.02	<0.01
Alanine aminotransferase	13.09±1.12	41.94±2.83	<0.001
Aspartate aminotransferase	32.72±1.77	54.76±2.87	<0.001
Alkaline phosphatase	92.77±1.23	122.63±1.44	<0.001

MCHC, mean corpuscular hemoglobin concentration; MCV, mean corpuscular volume.

Microscopic examination of blood films obtained from naturally infected camels showed presence of different morphological changes in erythrocyte such as tear droplet cells, elliptical cells, microcytes, microcytes with nuclear remnants, paler cells, stomatocytes, hypochromia and polychromia (Fig. 1). Previously various morphological alterations such as hypochromia, polychromia, stomatocyte, anisocytosis and poikilocytosis in experimentally infected rats and in naturally occurring cases of trypanosomiasis in camels have been reported (Abd El-Baky and Salem, 2011). Our results showed that in naturally infected camels the mean values of some serum biochemical parameters were significantly different when compared to healthy camels. Mean values of serum total proteins and albumin were significantly decreased in *Trypanosomiasis* positive camels as compared to healthy camels. Earlier studies also have reported hyperglobulinemia and hypoalbuminemia in camels which could be due to centrilobular degeneration and hepatic injuries associated with hypoxia (Chaudhary and Iqbal, 2000; Ahmad *et al.*, 2004).

Significantly increased values of different hepatic enzymes such as ALT, AST and ALP were also recorded. These increased values of hepatic enzymes could be due

to centrilobular degeneration as a result of the hypoxia and severe oxidative stress induced by parasitic infection. Similar changes also have been reported in rats and camels due to trypanosomiasis (Ahmad *et al.*, 2004; Abd El-Baky and Salem, 2011).

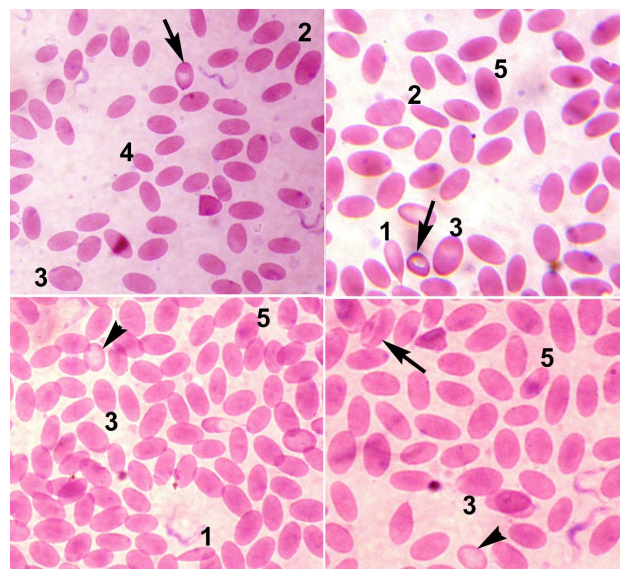


Fig. 1. Blood smear of trypanosomiasis affected camel showing tear droplet cells (1), elliptical cells (2), macrocyte (3), microcyte (4), cells with nuclear remnants (5), paler cells (arrow head) and stomatocytes (arrow). (Giemsa Stained- 1000X).

## CONCLUSION

From the findings of this study it can be concluded that trypanosomiasis is prevalent in reared in desert condition of Pakistan. This study may be a scope for further investigations and identification of trypanosomiasis associated vectors.

## REFERENCES

- Abd El-Baky, A.A. and Salem, S.I., 2011. Clinicopathological and cytological studies on naturally infected camels and experimentally infected rats with *Trypanosoma evansi*. *World appl. Sci. J.*, **14**: 42-50.
- Ahmad, S., Butt, A.A., Muhammad, G., Athar, M. and Khan, M.Z., 2004. Haematobiochemical studies on the haemoparasitized camels. *Int. J. Agric. Biol.*, **6**: 331-334.
- Ali, I., Chaudhry, M.S. and Farooq, U., 2009. Camel rearing in Cholistan desert of Pakistan. *Pakistan Vet. J.*, **29**: 85-92.
- Ali, F., Lodhi, L.A., Hussain, R. and Sufyan, M., 2014.

- Oxidative status and some serum macro minerals during estrus, anestrus and repeat breeding in Cholistani cattle. *Pakistan Vet. J.*, **34**: 532-534.
- Al-Rawshdeh, O.F., Sharif, L.A., Al-Qudah, K.M. and Al-Ani, F.K., 2003. Trypanosoma evansi infection in camels in Jordan. *Vet. Des. Trop.*, **20**: 233-237
- Anonymous, 2013-14. *Economic survey of Pakistan*. Finance division, economic advisors wing, ministry of finance, government of Pakistan, Islamabad, pp. 134.
- Asi, M.N., Lodhi, L.A., Mughal, M.N., Abbas, G., Muhammad, G. and Saqib, M., 2014. Nutritional secondary hyperparathyroidism in an African lion cub (*Pantheraleo*). *Pakistan Vet. J.*, **34**: 554-556.
- Aslam, A., Chaudhary, Z. I., Rehman, H., Ashraf, K., Ahmad, N., Yaqub, T., Maqbool, A. and Shakoori, A.R., 2010. Comparative evaluation of parasitological, serological and DNA amplification methods for diagnosis of natural Trypanosomal infection in Equines. *Pakistan J. Zool.*, **42**: 371-376
- Bhutto, B., Gadahi, J.A. Shah, G., Dewani, P. and Arijio, A.G., 2010. Field investigation on the prevalence of trypanosomiasis in camels in relation to sex, age, breeds and herd size. *Pakistan Vet. J.*, **30**: 175-177
- Bogale, B., Kelemework, F. and Chanie, M., 2012. Trypanomosis in camel (*Camelus dromedarius*) in Delo-Mena District, Bale Zone, Oromia Region, Southwest Ethiopia. *Acta Parasitol. Glob.*, **3**: 12-15
- Chaudhary, Z.I. and Iqbal, J., 2000. Incidence, biochemical and haematological alterations induced by natural trypanosomosis in racing dromedary camels. *Acta Trop.*, **77**: 209-213.
- Coura, J.R. and Borges-Pereira, J., 2010. Chagas disease: 100 years after its discovery. A systemic review. *Acta Trop.*, **115**: 5-13.
- Desquesnes, M., Holzmuller, P., Lai, D-H., Dargantes, A., Lun, Z-R. and Jittaplaong, S., 2013. *Trypanosoma evansi* and Surra: A Review and perspectives on origin, history, distribution, taxonomy, morphology, hosts and pathogenic effects, *BioMed. Res. Int.* <http://dx.doi.org/10.1155/2013/194176>.
- Dyary, H.O., Arif, A.H., Sharma, R.S.K. and Rasheed, A., 2014. Antitrypanosomal and cytotoxic activities of selected medicinal plants and effect of *Cordylineterminalis* on trypanosomal nuclear and kinetoplast replication. *Pakistan Vet. J.*, **34**: 444-448.
- Elamin, E., Bashir, E. and Saeed, E., 1998. Prevalence and infection pattern of *Trypanosoma evansi* in camels in mid-eastern Sudan. *Trop. Anim. Hlth. Prod.*, **30**:107-114
- El-Dakhly, KH. M., El-Habashi, N., El-Nahass, E., Sakai, H. and Yanai, T., 2013. Toxoplasmosis in the eastern grey kangaroo, *Macropus giganteus* and the cape hyrax, *Procavia capensis*, in Japan. *Pakistan Vet. J.*, **33**: 529-531.
- Elhaig, M.M., Youssef, A.I. and El-Gayar, A.K., 2013. Molecular and parasitological detection of trypanosomaevansi in camels in Ismailia, Egypt. *Vet. Parasitol.*, **198**: 214-218.
- Enwezor, F.N.C. and Sackey, A.K.B., 2005. Camel trypanosomosis – a review. *Vet. Arh.*, **75**: 439-452.
- Eyob, E. and Matios, L., 2013. Review on camel trypanosomosis (Surra) due to *Trypanosoma evansi*: Epidemiology and host response. *J. Vet. Med. Anim. Hlth.*, **5**: 334-343.
- Gad, S.B. and El-Maddawy, Z.K., 2014. Silymarin improves pancreatic endocrine function in rats. *Pakistan Vet. J.*, **34**: 214-218.
- Ghaffar, A., Ashraf, S., Hussain, R., Hussain, T., Shafique, M., Noreen, S. and Aslam, S., 2014. Clinico-hematological disparities induced by triazophos (organophosphate) in Japanese quail. *Pakistan Vet. J.*, **34**: 257-259
- Gutierrez, C., Corbera, J.A., Juste, M.C., Doreste, F. and Morales, I., 2005. An outbreak of abortions and high neonatal mortality associated with *Trypanosoma evansi* infection in dromedary camels in the Canary Islands. *Vet. Parasitol.*, **30**:163-168.
- Hussain, R., Khan, A., Mahmood, F., Rehan, S. and Ali, F., 2014. Clinico-hematological and tissue changes induced by butachlor in male Japanese quail (*Coturnix japonica*). *Pestic. Biochem. Physiol.*, **109**: 58-63
- Ismael, A.B., Swelum, A.A., Khalaf, A.F. and Abouheif, M.A., 2014. Clinical, haematological and biochemical alterations associated with an outbreak of theileriosis in dromedaries (*Camelus dromedarius*) in Saudi Arabia. *Pakistan Vet. J.*, **34**: 209-213.
- Kassa, T., Eguale, T. and Chaka, H., 2011. Prevalence of camel trypanosomosis and its vectors in Fentale district, South East Shoa Zone, Ethiopia. *Vet. Arh.*, **81**: 611-621.
- Khan, S.A., Alauddin, M., Hassan, M.M., Islam, S.K.M.A., Hossain, M.B., Shaikat, A.H., Islam, M.N., Debnath, N.C. and Hoque, M.A., 2013. Comparative performance and hemato-biochemical profile of Jinding ducks in different production systems of Bangladesh. *Pakistan Vet. J.*, **33**: 113-116.
- Konnai, S., Mekata, H., Mingala, C.N., Abes, N.S., Gutierrez, C.A., Herrera, J.R., Dargantes, A.P., Witola, W.H., Cruz, L.C., Inoue, N., Onuma, M. and Ohashi, K., 2009. Development and application of a quantitative real-time PCR for the diagnosis of Surra in water buffaloes. *Infect. Genet. Evol.* **9**: 449-452.
- Mihret, A. and Mamo, G., 2007. Bovine Trypanosomosis in three districts of East Gojjam Zone, bordering the Blue Nile River in Ethiopia. *J. Infect. Devel. Count.*, **1**: 321-325.
- Mijares, A., Vivas, J., Abad, C., Betancourt, M., Piñero, S., Proverbio, F., Marín, R. and Portillo, R., 2010. *Trypanosoma evansi*: Effect of experimental infection on the osmotic fragility, lipid peroxidation and calcium-ATPase activity of rat red blood cells. *Experiment. Parasitol.*, **124**: 301-305.
- Murtaz, U., Ghulam, M., Carlos, G., Zafar, I., Abdul, S. and

- Abdul, J., 2006. Prevalence of *Trypanosoma evansi* infection in equines and camels in the Punjab Region Pakistan. *Anals. N.Y. Acad. Sci.*, **1081**: 322-324
- Njiru, Z.K., Bett, O., Ole-mapeny, I.M., Githiori, J. and Ndungu, J.M., 2002. Trypanosomosis and helminthosis in camels. Comparison of ranch and traditional camel management systems in Kenya. *J. Camel Res. Pract.*, **55**: 67-71.
- Olaho-Mukani, W. and Mahamat, H., 2000. *Trypanosomiasis in the dromedary camel*. The Camelid Publishers Chandan Sagar Well Bikaner, India. 175pp.
- Pacholek, X., Gamatic, D., Franek, S.G. and Tibayrene, R., 2001. Prevalence of *Trypanosoma evansi* trypanosomosis in young camels in west Niger. *Rev. D'elev. Med. Vet. Pays Trop.*, **44**: 177-182.
- Padmaja, K., 2012. Haemato-biochemical studies and therapy of trypanosomiasis in camels. *Vet. World*, **5**: 356-358.
- Pathak, K.M., Arora, J.K. and Kapoor, M., 1993. Camel trypanosomosis in Rajasthan, India. *Vet. Parasitol.*, **49**: 319-323.
- Qureshi, A.S., Yaqoob, F. and Enbergs, H., 2013. Hematologic, metabolite and hormone responses to weaning-induced stress in foals of different breeds. *Pakistan Vet. J.*, **33**: 500-504.
- Rami, M., Atarhouch, T., Bendahman, M.N., Azlaf, R., Kechna, R. and Dakkak, A., 2003. Camelstrypanosomosis in Morocco. A pilot disease control trial. *Vet. Parasitol.*, **115**: 223-231.
- Reid, S.A., 2002. Trypanosomaevansi control and containment in Australasia. *Trends Parasitol.*, **18**: 219-224
- Reid, S.A., Husein, A., Partoutomo, S. and Copeman, D. B., 2001. The susceptibility of two species of wallaby to infection with *Trypanosoma evansi*. *Austral. Vet. J.*, **79**: 285-288.
- Rodríguez, N.F., Tejedor-Junco, M.T., González-Martín, M., Santana Del Pino, A. and Gutiérrez, C., 2012. Cross-sectional study on prevalence of *Trypanosoma evansi* infection in domestic ruminants in an endemic area of the Canary Islands (Spain). *Prev. Vet. Med.*, **1**:144-148.
- Salim, B., Mohammed, A.B., Joseph, K., Ichiro, N. and Chihiro, S., 2011. Molecular epidemiology of camel trypanosomiasis based on ITS1 rDNA and RoTat 1.2 VSG gene in the Sudan. *Parasit. Vect.*, **4**: 31.
- Shafqaat, A., Butt, A.A., Muhammad, G., Athar, M. and Khan, M.Z., 2004. Haematobiochemical studies on the haemoparasitized camels. *Int. J. Agric. Biol.*, **6**: 331-334.
- Shah, S.R., Phulan, M.S., Memon, M.A., Rind, R. and Bhatti, W.M., 2004. Trypanosomes infection in camels. *Pakistan Vet. J.*, **24**: 209-210.
- Shahid, M., Janjua, S., Abbas, F.I. and Burbach, J.S., 2013. PCR-based detection of *Trypanosoma evansi* infection in semi-captive Asiatic black bears (*Ursusthibetanus*). *Pakistan Vet. J.*, **33**: 442-445.
- Soylu, E., 2013. Metazoan parasites of perch *Perca fluviatilis* L. from Lake Siğircı, Ipsala, Turkey. *Pakistan J. Zool.*, **45**: 47-52.
- Sood, N.K., Singla, L.D., Singh, R.S. and Uppal, S.K., 2011. Association of *Trypanosoma theileri* with peritonitis in a pregnant cross-bred cow: A case report. *Vet. Med.*, **56**: 82-84.
- Tadesse, A., Omar, A., Aragaw, K., Mekbib, B. and Sheferaw, D.A., 2012. Study on camel Trypanosomosis in Jijiga Zone, Eastern Ethiopia. *J. Vet. Adv.*, **2**: 216-219.
- Zayed, A.A., Habeeb, S.M., Allam, N.A.T., Ashry, H.M.Z., Mohamed, A.H.H., Ashour, A.A. and Taha, H.A., 2010. A critical comparative study of parasitological and serological differential diagnostic methods of *Trypanosoma evansi* infections in some farm animals in Egypt. *Am. Eur. J. Agric. environ. Sci.*, **8**: 633-642
- Zelege, M. and Bekele, T., 2001. Camel herd health and productivity in eastern Ethiopia selected semi-nomadic households. *Med. Vet. Des Pays Trop.*, **55**: 213-217.